AMERICAN ACADEMY™ OF OPHTHALMOLOGY

Large (9 mm) Deep Anterior Lamellar Keratoplasty with Clearance of a 6-mm Optical Zone Optimizes Outcomes of Keratoconus Surgery

Massimo Busin, MD,[1,2] *Pia Leon, MD,*[1,2,3] *Yoav Nahum, MD,*[1,2,4,5] *Vincenzo Scorcia, MD*[1,2,6]

Purpose: To evaluate the outcomes of a 9-mm deep anterior lamellar keratoplasty (DALK) with removal of the deep stroma limited to the central 6-mm optical zone.

Design: Prospective, noncomparative, interventional case series.

Participants: A total of 80 consecutive keratoconic eyes without deep stromal scarring, with at least 1 postoperative examination 1 month after complete suture removal.

Intervention: A standardized DALK was performed, including (1) deep trephination of the recipient bed 450 to 550 μm in depth and 9 mm in diameter; (2) pneumatic dissection; (3) debulking of approximately 80% of the anterior stroma; (4) removal of the deep stroma (bubble roof) from a central 6-mm optical zone; and (5) transplantation of a 9-mm anterior corneal lamella cut by microkeratome-assisted dissection (400-μm head) and sutured with a double running 10-0 nylon suture.

Main Outcome Measures: Success rate and type of pneumatic dissection obtained; best spectacle-corrected visual acuity (BSCVA), refractive astigmatism (RA), and topographic astigmatism (TA), central corneal thickness (CCT) and endothelial cell density 12 months postoperatively; and intraoperative and postoperative complications.

Results: Pneumatic dissection created a "big bubble" in 67 of 80 eyes (83.7%), all of them but 1 (1.5%) being of type 1 according to the classification by Dua et al. After complete suture removal, BSCVA averaged 0.09±0.72 logarithm of the minimum angle of resolution (logMAR) and was ≥20/20 in 28 eyes (35%), ≥20/25 in 54 eyes (67.5%), and ≥20/40 in 76 eyes (95%); RA averaged 3.10±1.30 diopters (D), with 73 eyes (91%) within 4.5 D and none above 6 D; regular TA was detected in 72 eyes (90%); mean CCT was 492±62.10 μm; postoperative endothelial cell density averaged 2026±397cells/mm^2 with a mean cell loss of 11.2%. Intraoperative complications included loss of suction (n = 1) and perforation (n = 4). No conversion to penetrating keratoplasty was necessary. After surgery, double anterior chamber was observed in 2 cases (2.5%), both managed successfully by air filling of the anterior chamber. Stromal rejection was observed in 6 eyes (7.5%) and was reversed with topical steroids in all cases.

Conclusions: In keratoconic eyes without deep stromal scars, the combination of a graft larger than conventional ones with limited removal of deep stroma can improve visual and refractive outcomes of DALK, while minimizing the rate of complications. *Ophthalmology 2017;124:1072-1080 © 2017 by the American Academy of Ophthalmology*

Supplemental material available at www.aaojournal.org

As shown by the 2015 annual report of the American Eye Bank Association, deep anterior lamellar keratoplasty (DALK) represents only 2.3% of the total number of corneal transplantations performed in the United States, increasing to 3% if tissues exported to other countries are included in the calculation.[1–3] These data show that surgeons weigh the undisputed advantage of preserving the recipient endothelium against other issues that make them prefer to perform a penetrating keratoplasty (PK) in the majority of eyes that could instead benefit from DALK, such as eyes with keratoconus (KC).

Three main arguments usually are put forward against performing DALK for KC, namely, the rarity of complications reported for PK, the lack of standardization in the surgical technique of DALK, and the lack of substantial advantages of DALK over PK in regard to visual and refractive outcomes.[4,5] Several studies contradict the first 2 arguments: A relevant percentage of short-term and long-term complications of PK has been reported, and several techniques have been presented over the years to simplify and standardize DALK.[6,7] Instead, all scientific articles published to date have shown values of post-DALK visual

http://dx.doi.org/10.1016/j.ophtha.2017.02.011
ISSN 0161-6420/17

acuity and residual refractive error matching at best those recorded after PK.[8–10]

With the purpose of profiting from the refractive advantages of large grafts, while trying to minimize the risks of complications, especially conversion to PK, we have modified DALK using lamellar grafts 9.0 mm in diameter in combination with stromal clearance of an optical zone limited to the central 6.0 mm. We report the outcomes of this procedure.

Methods

All consecutive patients with KC without scars affecting the posterior third of the stroma, operated on by the same surgeon (M.B.) at "Villa Igea" Hospital (Forlì, Italy), according to the technique described in detail later, were included in a prospective clinical study undertaken at our institution, Villa Igea Hospital, since September 2013 and still in progress. The study followed the tenets of the 2013 Declaration of Helsinki and was approved by the local ethics committee (Comitato Etico Ospedali Privati Villa Serena-Villa Igea); a detailed informed consent was provided to all patients undergoing surgery. Preoperatively, all patients did not gain useful visual acuity with spectacles and were contact lens intolerant.

Demographic data were recorded, and every patient underwent a complete preoperative ophthalmological evaluation including slit-lamp examination, best spectacle-corrected visual acuity (BSCVA), refraction, tonometry, fundoscopy, endothelial specular microscopy (EM-3000; Tomey, Erlangen, Germany), and anterior segment optical coherence tomography (AS-OCT) (Casia; Tomey, Tokyo, Japan), from which both topographic and pachymetric maps were obtained. Intraoperatively, success or failure of pneumatic dissection, type and diameter of the bubble obtained, and complications were noted.

A thorough eye evaluation, including all preoperative examinations, was scheduled and performed in all patients between 6 and 9 months postoperatively, that is, after removal of 1 of the running sutures, as well as between 12 and 14 months postoperatively, that is, after complete suture removal. Postoperative complications occurring during the follow-up period were recorded. All data collected in the study were entered into an electronic database via Microsoft Excel 2007 (Microsoft Corp., Redmond, WA). Snellen visual acuity values were converted into the logarithm of the minimum angle of resolution (logMAR) scale for statistical purposes. Data were analyzed with the MedCalc Online Calculators (MedCalc Software, Mariakerke, Belgium). For the analysis of quantitative measures, we used the Student t test for normally distributed variables. Chi-square or Fisher exact test was used for the analysis of categoric variables. Differences were considered statistically significant when the P value was less than 0.05.

Surgical Procedure

In all patients, anesthesia and akinesia were obtained by means of peribulbar injection of 10 ml of a 0.75% ropivacaine solution (Video 1, available at www.aaojournal.org). As described previously in detail,[11] in all cases pneumatic dissection was attempted advancing a dedicated probe and then a cannula up to 2 mm centripetally from the bottom of a deep trephination, 450 to 550 μm in depth and 9 mm in diameter (Fig 1). To minimize the risk of perforation, because the measurable blade advancement can be regulated precisely only in 50-μm steps, the trephine was set to a variable depth, always intended within 100 μm from the thinnest AS-OCT measurement at the site of trephination (9 mm in diameter).

Regardless of the success of pneumatic dissection, in all cases the recipient cornea was debulked by performing an anterior keratectomy, which removed approximately 80% of the anterior stroma. Then a disposable handheld trephine was used to mark the central 6-mm optical zone. When pneumatic dissection succeeded, after measuring the diameter of the bubble, an adhesive viscoelastic substance (IAL-F, Fidia, Padova, Italy) was laid centrally onto the bubble roof and a 15° blade was used to enter the bubble. The inferior branch of a blunt Vannas scissor was inserted into the pre-descemetic space, and the slit was enlarged to allow corneal scissors to be used to complete the excision of the central deep stroma, following the 6-mm mark. Instead, if pneumatic dissection failed, layer-by-layer hand dissection was performed within the 6-mm mark, removing completely the emphysematous stroma, in an attempt at reaching the pre-descemetic layer. The donor cornea mounted on the artificial anterior chamber of the automated lamellar therapeutic keratoplasty system (Moria, Antony, France) was dissected by means of a 400-μm microkeratome head. The anterior lamella obtained this way was punched to a diameter of 9 mm and sutured into the recipient bed using a double running 10-0 nylon suture. The final corneal architecture included a peripheral crown approximately 1.5 mm in width resulting from the overlap of the donor lamella on the residual deep stroma of the recipient, as well as a 6.0-mm central optical zone somewhat thinner than normal central cornea, where the donor tissue was laid directly onto the pre-descemetic bubble floor (Fig 2). At the end of the procedure, the anterior chamber was filled with balanced salt solution injected through the side entry created immediately before the pneumatic dissection was attempted, as per the technique previously described.[11]

Triamcinolone acetonide and gentamicin sulfate, 0.3%, were injected subconjunctivally at the end of the procedure, and the eye was patched. Beginning the following morning, dexamethasone phosphate, 0.1%, and tobramycin sulfate, 0.3%, antibiotic eye drops were administered every 2 hours, then tapered off to a single daily steroidal administration 1 month after partial suture removal, and finally discontinued at month 8 from surgery. In every patient, 1 of the 2 running sutures was removed 2 to 3 months postoperatively, whereas the second suture was removed within 10 months from surgery in patients aged less than 30 years and within 12 months from surgery in all other patients.

Results

Since the introduction of this technique into our surgical routine, full evaluation after complete suture removal has been performed in 80 eyes of 80 patients. Twenty-eight of these were female patients and 52 were male patients; their age ranged from 12 to 71 years (average ± standard deviation = 36.3±13.1).

Pneumatic dissection succeeded in 67 eyes (83.7%), whereas hand dissection was performed in the remaining 13 eyes (16.3%). A purely Descemetic bubble (type 2 according to the classification reported by Dua et al[12]) was obtained in only 1 eye (1.5%), whereas in all other cases the bubble was of type 1. The average size of the bubbles obtained was 7.7±0.8 mm (range, 6–9 mm).

Mean BSCVA improved significantly from 0.54±0.85 logMAR preoperatively to 0.18±0.74 logMAR after removal of 1 suture ($P < 0.01$) and further significantly to 0.009±0.72 logMAR ($P = 0.001$) after complete suture removal. The BSCVA was ≥20/20 in 7 eyes (8.7%), ≥20/25 in 19 eyes (23.75%), and ≥20/40 in 61 eyes (76.25%) after removal of 1 suture and ≥20/20 in 28 eyes (35%), ≥20/25 in 54 eyes (67.5%), and ≥20/40 in 76 eyes (95%) after complete suture removal. Reasons for BSCVA below 20/40 (4 eyes) included amblyopia (n = 3) and cataract formation (n = 1). At the final examination time, BSCVA of eyes with

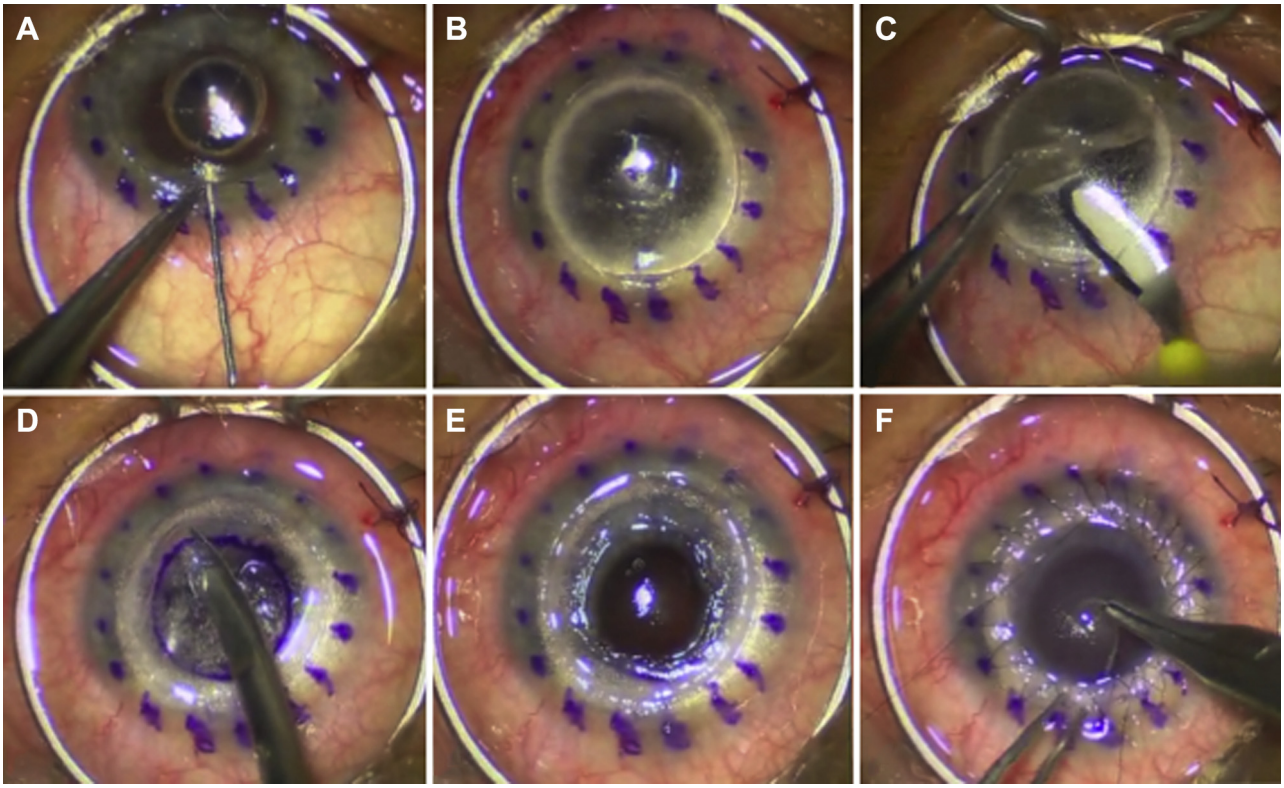

Figure 1. Intraoperative images of the different surgical steps of deep anterior lamellar keratoplasty (DALK). **A**, Insertion of a dedicated cannula from the base of a 9-mm deep trephination approximately 2 mm into the central cornea. **B**, Pneumatic dissection. **C**, Debulking of approximately 80% of the anterior stroma. **D**, Removal of the deep stroma (bubble roof) from a central 6-mm optical zone. **E**, Recipient bed consisting of a 6-mm central pre-descemetic area surrounded by a crown of deep stroma, approximately 1.5 mm in width. **F**, Transplantation of a 9-mm anterior corneal lamella sutured with a double running 10-0 nylon suture.

successful pneumatic dissection did not differ significantly from that of eyes with hand dissection ($P = 0.12$).

The mean absolute value of refractive astigmatism decreased significantly ($P = 0.002$) from 7.2 ±2.5 diopters (D) (range, 3−10 D) preoperatively to 3.2±1.50 D (range, 0−7 D) after removal of 1 suture and remained substantially stable at 3.10±1.30 D (range, 0−6 D) after complete suture removal. At this last examination time, 73 eyes (91%) were within 4.5 D and none above 6 D; the mean spherical equivalent was −1.55±3.3 D. Topographic astigmatism did not vary substantially from refractive astigmatism: At the last examination time it averaged 3.26±1.16 D with a mean asymmetry value in the 3 mm central zone of 1.01±0.15 D.

After complete suture removal, central corneal thickness (CCT) averaged 462.48±62.10 μm (range, 401−519 μm). A discrete layer of residual stroma was not seen in any of the AS-OCT pictures regardless of the type of dissection performed. Morphologic examination of the posterior corneal contour could not detect a step at the edge of the 6-mm optical zone in any eye (Fig 3).

Postoperative endothelial cell density averaged 2026±397cells/mm^2 with a mean cell loss of 11.2% from the preoperative value. Surgery was complicated by perforation at the end of trephination in 1 case, which could be completed anyway by means of pneumatic dissection obtained by inserting the cannula at a site approximately 3 hours of the clock away from the perforation. In 3 additional cases that required hand dissection, microperforations occurred but did not necessitate conversion to PK. During the postoperative course, stromal immunologic rejection was seen in 6 eyes (7.5%) and was reverted completely with topical steroids in all cases. Inadvertent rupture and consequent removal of both running sutures occurred in 1 case as early as 3 months after surgery. No dehiscence of the surgical wound was seen at any time. Early postoperative Descemet's membrane detachment occurred in 2 eyes (2.5%) and was managed successfully with single air filling of the anterior chamber both times. None of these eyes had had a microperforation, which was therefore not identified as a factor associated with increased risk for detachment ($P = 1$).

Discussion

Deep anterior lamellar keratoplasty has undisputed advantages over PK in terms of endothelial survival and complication rates.[4−10,13,14] However, many surgeons are still reluctant to embrace this procedure, mainly because pneumatic dissection is difficult to master, but also because refractive and visual outcomes of DALK at best do not differ substantially from those of PK. The simplest way to attempt at improving postoperative refractive outcomes may be to use larger grafts, which have been reported to yield more regular astigmatism,[15] but full-thickness grafts larger than 8 mm in diameter are associated with an increased risk of endothelial immunologic rejection and are not normally used for PK. Instead, lamellar grafts of larger diameter can be used for DALK, because no endothelial rejection is possible and eventual stromal or epithelial rejections can be

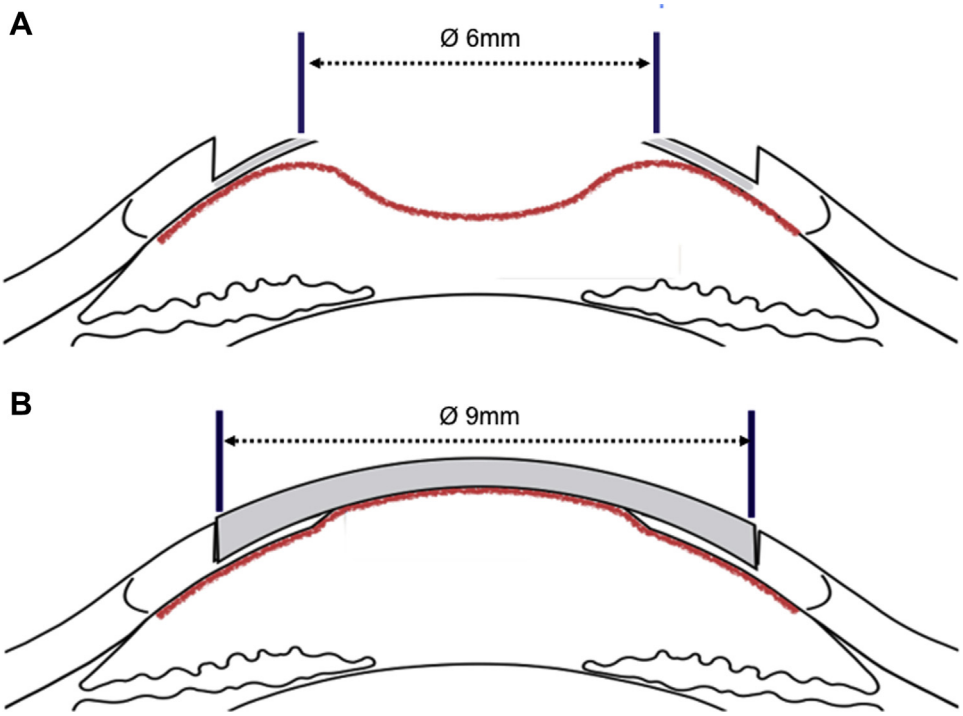

Figure 2. Schematic illustration of modified deep anterior lamellar keratoplasty (DALK). **A**, Exposure of a central pre-descemetic area surrounded by a crown of deep stroma, approximately 1.5 mm in width. **B**, Final corneal configuration showing direct contact of the donor tissue with the predescemetic part of the recipient bed in the central 6-mm area.

managed successfully with conservative treatment in most cases. As recently published in a relatively small study, lamellar grafts larger than 8 to 8.25 mm in diameter may provide better astigmatic outcomes than smaller ones.[16] However, when conversion to PK is necessary, especially at the beginning of the surgeon's learning curve, a full-thickness graft larger than 8 mm would be required to manage this complication and therefore increase the risk for immunologic rejection.[17] In addition, with the current techniques, pneumatic dissection does not usually extend beyond 7.5 to 8.0 mm and would have to be completed by hand to reach beyond this size, thus posing an additional challenge to the surgeon and increasing the chances of requiring conversion to PK.

To address all these limitations while allowing the use of lamellar grafts 9 mm in diameter, we have modified DALK, introducing the concept that the diameter of the lamellar graft can be larger than that of the stromal clearance. In all the eyes included in this series, a 9-mm graft was transplanted, but the optical zone was cleared only in the central 6 mm.

A trephination larger than the conventional ones (8–8.25 mm in diameter) offers the advantage of

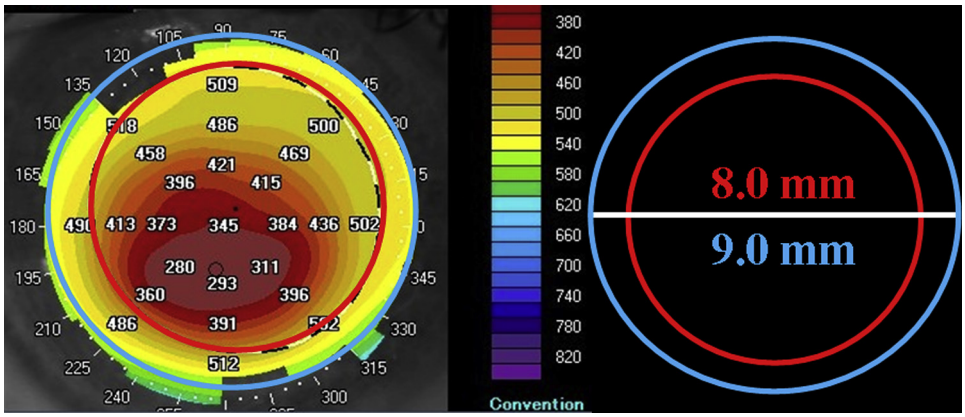

Figure 3. Anterior segment optical coherence tomography (AS-OCT) and slit-lamp images of the same eye at day 2 (**A** and **B**), month 6 (**C** and **D**), and year 1 (**E** and **F**) after deep anterior lamellar keratoplasty (DALK). Remodeling over time of the corneal architecture is clearly visible, with progressive disappearance of the posterior step at the edge of the 6-mm zone.

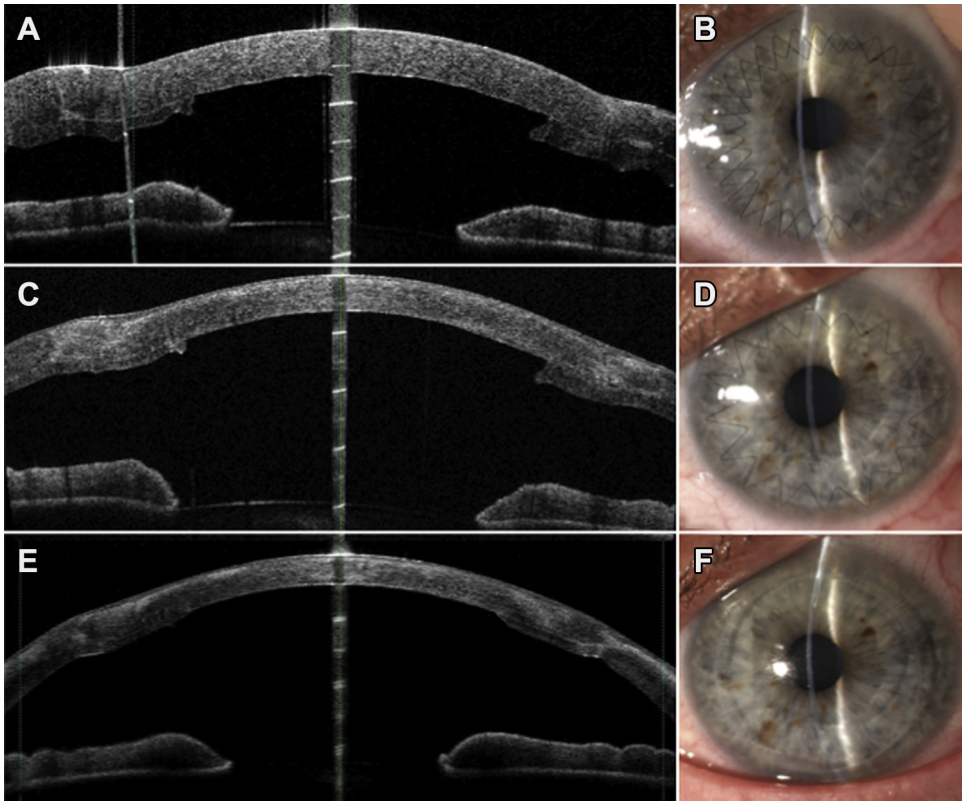

Figure 4. Pachymetric map of a keratoconic eye of the broad-base type. Only the 9-mm diameter includes the whole ectasia.

comprising in most eyes the whole ectasia, especially when the KC is of the broad-base type (Fig 4), thus allowing a safer trephination into the deep stroma and suturing of donor tissue into a more regular recipient bed. As recently published,[11] the deep trephination used for our technique optimizes the success rate of pneumatic dissection while being complicated by accidental perforation in a low percentage of cases (1 of 80 cases = 1.2%), without compromising the possibility of completing the procedure as initially planned. The block of the suction trephine with measurable blade advancement can be predetermined accurately on the base of the pachymetric map obtained by means of AS-OCT and is instrumental for the success of this technique.

Postoperative BSCVA of 9-mm DALK compares favorably with that recorded after conventional DALK with smaller grafts, averaging 0.18±0.74 logMAR after removal of 1 suture and 0.009±0.72 logMAR (P = 0.001) after

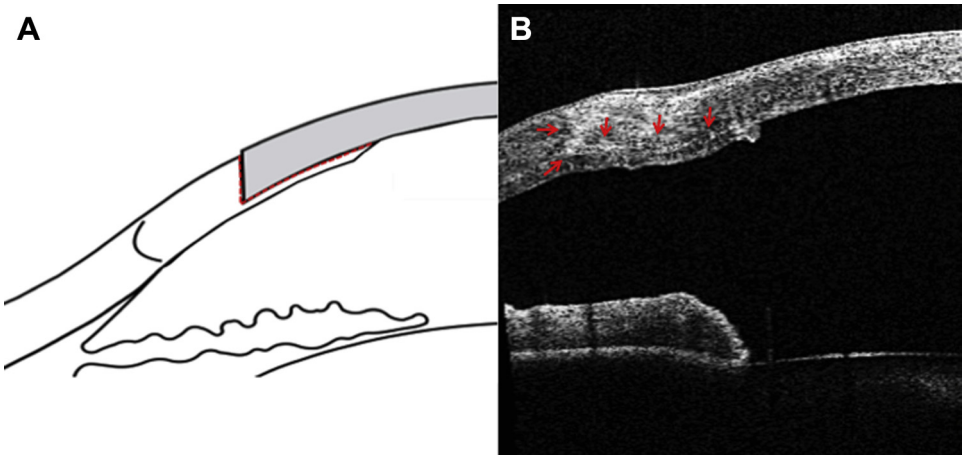

Figure 5. Schematic (**A**) and postoperative (6 months) anterior segment optical coherence tomography (AS-OCT) image (**B**) of the "lap-joint" type of wound configuration obtained with the modified deep anterior lamellar keratoplasty (DALK) technique. Dashed red lines and red arrows signify the donor-recipient interface.

Table 1. Comparative Outcomes 1 Year after Deep Anterior Lamellar Keratoplasty

Authors	Bubble Success* (%)	Perforation (%)	Conversion to PK (%)	Trephination Size (mm)	Mean BSCVA (logMAR)	Mean RA or TA (D)	RA or T4A <4–4.5 D (%)	RA or TA Range (D)	SE (D)	ECL (%)
Fontana et al, 2007[18]	64	13	4	8.00–9.00	0.14±0.74	2.94±1.45[†,#]	84[†,**]	1–7.13[†,#]	−1.81±3.2	17
Feizi et al, 2010[21]	81.7	4	2.4	8.18±0.1	0.24±0.21[‡] 0.32±0.14[§]	NA	NA	NA	−2.8	NA
Sarnicola et al, 2010[22]	59	10.5	1.2	8.00–8.50	0.09	3.676[#]	NA	0.52–8.47[#]	NA	12
Riss et al, 2012[24]	80	11.9	16	8.0±0.25	0.3±0.8[‖]	4.13±2.41[#]	NA	0.37–9.73[#]	−2.11±1.2	17.5
Smadja et al, 2012[34]	57.1	31.8	27.3	8.00	0.05±0.85	2.33±1.35[¶]	NA	NA	−3.68±2.84	NA
Ghanem et al, 2015[35]	81.8	15.6	4.5	7.3–8.5	0.2±0.1	NA	NA	NA	NA	NA
Knutsson et al, 2015[23]	77	10	10	8.00–8.25	0.11±0.08[‡] 0.13±0.08[§]	3.23±2.07[‡,¶] 3.93±1.87[§,¶] 3.02±1.84[‡,#] 3.77±2.13[§,#]	NA	NA	NA	NA
Busin et al, 2016	83.7	3.75[‡‡]	0	9.00	0.09±0.72	3.10±1.30[¶] 3.26±1.16[#]	91[††] 91[§§]	0–6[¶] 0.38–6.10[#]	−1.55±3.3	11.2

BSCVA = best spectacle-corrected visual acuity; ECL = endothelial cell loss; NA = not available; PK = penetrating keratoplasty; RA = refractive astigmatism; SE = spherical equivalent; TA = topographic astigmatism.
*Success rate of pneumatic dissection.
[†]Outcomes at 2-year follow-up.
[‡]Results in bared Descemet's membrane cases.
[§]Results in manual dissection cases.
[‖]Sutures still in place.
[¶]Refractive astigmatism.
[#]Topographic astigmatism.
**Topographic astigmatism <4 D.
[††]Refractive astigmatism <4.5 D.
[§§]Topographic astigmatism <4.5 D.
[‡‡]Excluding 1 perforation during trephination.

complete suture removal. Final BSCVA was ≥20/20 in 28 eyes (35%), ≥20/25 in 54 eyes (67.5%), and ≥20/40 in 76 eyes (95%), thus always at the upper limit of or beyond the ranges of values published in previous articles (16.2%−23% for BSCVA ≥20/20, 50%−73% for BSCVA ≥20/25, and 80%−95% for BSCVA ≥20/40).[7,13,18] In addition, the values considered in these reports were recorded at follow-up times from surgery considerably longer (2−8 years) than ours, thus allowing a longer time for visual recovery.[18]

Although some authors have reported that BSCVA after hand dissection is significantly worse than after successful pneumatic dissection,[7,10,18−20] similar to what has been reported by other authors,[13,21−23] we could not see any significant difference in our population after complete suture removal. This is probably a consequence of the variable amount of residual stroma left in place by different surgeons. In the report by Borderie et al,[7] the average thickness of the residual recipient stroma in the manual dissection group measured by AS-OCT was 87 μm, reaching up to 150 μm, whereas in our series after complete suture removal, the residual stroma could not be seen and was measured at the slit lamp or by AS-OCT.

The final mean absolute value of refractive astigmatism recorded in our series was 3.10±1.30 D, thus supporting previous evidence that post-DALK astigmatism is lower if grafts larger than 8 mm in diameter are transplanted.[15,16] In addition, only 7 eyes (8.75%) had more than 4.5 D of refractive astigmatism, and none had more than 6 D. Fontana et al[18] reported that after complete suture removal, topographic cylinder greater than 4 D and 5 D was measured in 16.6% and 6.7% of eyes, respectively, in their series. In other articles, postoperative astigmatism was found to reach values greater than 8 D[22] and 9 D.[24]

In our series, we also addressed the issue of regularity of postoperative astigmatism and recorded after complete suture removal a mean asymmetry value in the 3-mm central zone of 1.01±0.15 D, thus explaining the excellent visual outcomes and in particular the high rate of eyes seeing 20/20 or better with spectacles. Unfortunately, in this regard no comparison is possible with other series, because no other study has evaluated the topographic regularity of post-DALK astigmatism.

Large lamellar grafts for patients with KC may have the additional advantage of extending more peripherally the excision of pathologic recipient stroma. Because debulking is limited to approximately 80% of the anterior stroma, with our technique transplantation of an anterior donor lamella dissected by means of a 400-μm microkeratome head normalizes the thickness of the peripheral cornea beyond the 8-mm diameter of a conventional DALK. Recurrence of KC in the graft has been reported after a mean latency period of 18 years after PK in up to 12% of patients and is considered related to the existence of the disease in the residual host stroma.[6,25] Long-term results of DALK may show a difference in the recurrence rate of KC, if any, based on the amount of residual pathologic stroma left in place.

Limiting the clearance of the optical zone to 6 mm represents the true innovation introduced by our technique. This eliminates the need for peripheral dissection when the bubble does not extend up to the trephination. It also reduces the risk of perforation when pneumatic dissection fails, because hand dissection has to be carried out over an area 6 mm in diameter (28.26 mm^2), which is approximately only 50% of the extension of an 8- to 8.25-mm area (50.24−53.42 mm^2). Micro-perforation occurred in a small percentage of eyes of our series and always could be managed by hand dissection (3 of 80 cases = 3.7%), whereas conversion to PK was never necessary. However, as we previously reported, should macro-perforations occur, then rather than a 9-mm PK, we would perform a 2-piece mushroom keratoplasty, which replaces only the central 6 mm of deep stroma and endothelium.[26] Alternatively, for those who are not familiar with this technique, a 1-piece mushroom-shaped graft can be transplanted after preparation by manual[27] or femtosecond laser-assisted[28−30] dissection. Only less-experienced cornea surgeons, who may not master any of these techniques, would have to convert to a 9.0-mm PK and should be aware of the risks related to large PKs before attempting to perform 9.0-mm DALK.

Clearing only a 6-mm central zone and leaving a peripheral crown of recipient stroma (∼1.5 mm in width) creates a new corneal architecture under the donor lamella, which could offer both advantages and disadvantages.

However, postoperative CCT is lower than that obtained after transplantation of a whole donor cornea and the peripheral stroma is incised for 360°, but recurrence of ectasia was not seen in any case of our series. In addition, the final CCT values were higher than 250 μm (the thickness of deep stroma considered the limit for the risk of developing ectasia after LASIK[31]), and the anterior lamella transplanted with our procedure included anterior stroma and a normal Bowman's layer, which offer a higher resistance to ectasia than deep stroma does.

Another possible argument against our method could be the irregularity in the posterior corneal curvature created by the step at the edge of the 6-mm zone. However, no patient reported any specific symptom regarding the quality of their vision even at night, and in all cases the step itself disappeared within few months from surgery as demonstrated by the AS-OCT images (Fig 3). Refraction was not affected by this remodeling of the stroma, and the average spherical equivalent recorded in our series after suture removal does not show any substantial difference from the values recorded after conventional DALK in other series.

Finally, 9.0-mm lamellar grafts may be more susceptible to epithelial and stromal rejection episodes than lamellar graft of lower diameter. Especially in atopic patients, the latter ones can be accompanied by corneal neovascularization and lipid deposition, which can reduce vision to a great extent. In our series, slow tapering of steroids over an 8-month period limited the occurrence of stromal rejection to 6 cases (all treated successfully with topical steroids) and may have prevented further complications, such as the development of stromal neovessels and lipid deposition, which were not seen in any of our cases. However, the relatively short follow-up of our study does not allow to draw conclusions about the long-term safety of our technique in regard to possible immunologic complications.

On the positive side, unlike for conventional DALK, in our variant the 9-mm trephination need not be hand refined, thus creating a machine-cut perfectly circular incision, with optimal apposition to the punched graft, a feature that could contribute to optimize the regularity of the postoperative corneal profile. Furthermore, the "lap joint" type of wound configuration obtained with our DALK modification creates a large surface (Fig 5) of contact between donor and recipient stroma, possibly leading to faster wound healing and improved mechanical stability, as well as allowing earlier suture removal with earlier visual recovery.[29,32,33] In our series, no wound dehiscence was seen, although we completed suture removal within 10 months from surgery in all patients aged less than 30 years. In particular, a period of 3 months was sufficient to seal the wound in the patient who experienced inadvertent rupture and consequent removal of both sutures so early after surgery.

Finally, the crown of deep stroma surrounding the central debulked zone also protects the recipient bed from inadvertent perforations by the needle possibly occurring while suturing the donor tissue in place, a complication often reported anecdotally by surgeons, but for which no statistics are available in the literature.

Also in regard to intraoperative and postoperative complications, the outcomes of our technique compare favorably with those of previous reports. As shown in Table 1, we observed the lowest rate of intraoperative perforation and conversion to PK. Double chamber formation was seen in 2 cases (2.5%) and managed successfully by a simple air fill of the anterior chamber. This complication was reported previously in a similar percentage of cases.[22,24,35] In addition, despite the larger diameter of our grafts, stromal rejection was observed in a percentage of cases (7.5%) comparable to that reported by authors using smaller grafts (up to 10%).[7,24,35] Despite the larger size of the debulked area, the average ECL recorded 1 year after surgery in our series (11.2%) is within the range reported in the past.[22–24]

In conclusion, as summarized in Table 1, the success rates of pneumatic dissection and visual and refractive results obtained with our DALK modification (transplantation of a 9-mm lamellar graft combined with stromal clearance of a 6-mm optical zone) compare extremely favorably with those obtained with other DALK techniques, whereas the rate of intraoperative and postoperative complications is minimized.

References

1. Park CY, Lee JK, Gore PK, et al. Keratoplasty in the United States: a 10-year review from 2005 through 2014. *Ophthalmology*. 2015;122:2432-2442.
2. Mohamed-Noriega K, Angunawela RI, Tan D, Mehta JS. Corneal transplantation: changing techniques. *Transplantation*. 2011;92:e31-e32; author reply e32-e33.
3. *Eye Bank Association of America (EBAA) 2015 Eye Banking Statistical Report*. Washington, DC: Eye Bank Association of America; 2015. Available at: http://restoresight.org/wp-content/uploads/2016/03/2015-Statistical-Report.pdf. Accessed November 21, 2016.
4. Coster DJ, Lowe MT, Keane MC, Williams KA, Australian Corneal Graft Registry Contributors. A comparison of lamellar and penetrating keratoplasty outcomes: a registry study. *Ophthalmology*. 2014;121:979-987.
5. Chen G, Tzekov R, Li W, et al. Deep anterior lamellar keratoplasty versus penetrating keratoplasty: a meta-analysis of randomized controlled trials. *Cornea*. 2016;35:169-174.
6. Reinhart WJ, Musch DC, Jacobs DS, et al. Deep anterior lamellar keratoplasty as an alternative to penetrating keratoplasty a report by the American Academy of Ophthalmology. *Ophthalmology*. 2011;118:209-218.
7. Borderie VM, Sandali O, Bullet J, et al. Long-term results of deep anterior lamellar versus penetrating keratoplasty. *Ophthalmology*. 2012;119:249-255.
8. Keane M, Coster D, Ziaei M, Williams K. Deep anterior lamellar keratoplasty versus penetrating keratoplasty for treating keratoconus. *Cochrane Database Syst Rev*. 2014: CD009700.
9. Sutphin JE, Goins KM, Wagoner MD. Deep anterior lamellar keratoplasty: when should it replace penetrating keratoplasty? *Am J Ophthalmol*. 2009;148:629-631.
10. Han DC, Mehta JS, Por YM, et al. Comparison of outcomes of lamellar keratoplasty and penetrating keratoplasty in keratoconus. *Am J Ophthalmol*. 2009;148:744-751.
11. Busin M, Scorcia V, Leon P, Nahum Y. Outcomes of air injection within 2 mm inside a deep trephination for deep anterior lamellar keratoplasty in eyes with keratoconus. *Am J Ophthalmol*. 2016;164:6-13.
12. Dua HS, Faraj LA, Said DG, et al. Human corneal anatomy redefined: a novel pre-Descemet's layer (Dua's layer). *Ophthalmology*. 2013;120:1778-1785.
13. Kubaloglu A, Sari ES, Unal M. Long-term results of deep anterior lamellar keratoplasty for the treatment of keratoconus. *Am J Ophthalmol*. 2011;151:760-767.
14. Fogla R, Padmanabham P. Results of deep lamellar keratoplasty using the big-bubble technique in patients with keratoconus. *Am J Ophthalmol*. 2006;141:254-259.
15. Seitz B, Langenbucher A, Küchle M, Naumann GO. Impact of graft diameter on corneal power and the regularity of post-keratoplasty astigmatism before and after suture removal. *Ophthalmology*. 2003;110:2162-2167.
16. Huang T, Hu Y, Gui M, et al. Large-diameter deep anterior lamellar keratoplasty for keratoconus: visual and refractive outcomes. *Br J Ophthalmol*. 2015;99:1196-1200.
17. Skeens HM, Holland EJ. Large-diameter penetrating keratoplasty: indications and outcomes. *Cornea*. 2010;29: 296-301.
18. Fontana L, Parente G, Tassinari G. Clinical outcomes after deep anterior lamellar keratoplasty using the big-bubble technique in patients with keratoconus. *Am J Ophthalmol*. 2007;143:117-124.
19. Anwar M, Teichmann KD. Big-bubble technique to bare Descemet's membrane in anterior lamellar keratoplasty. *J Cataract Refract Surg*. 2002;28:398-403.
20. Tan DT, Anshu A, Parthasarathy A, Htoon HM. Visual acuity outcomes after deep anterior lamellar keratoplasty: a case-control study. *Br J Ophthalmol*. 2010;94:1295-1299.
21. Feizi S, Javadi MA, Jamali H, Mirbabaee F. Deep anterior lamellar keratoplasty in patients with keratoconus: big-bubble technique. *Cornea*. 2010;29:177-182.
22. Sarnicola V, Toro P, Gentile D, Hannush SB. Descemetic DALK and predescemetic DALK: outcomes in 236 cases of keratoconus. *Cornea*. 2010;29:53-59.
23. Knutsson KA, Rama P, Paganoni G. Modified big-bubble technique compared to manual dissection deep anterior

lamellar keratoplasty in the treatment of keratoconus. *Acta Ophthalmol*. 2015;93:431-438.
24. Riss S, Heindl LM, Bachmann BO, et al. Pentacam-based big bubble deep anterior lamellar keratoplasty in patients with keratoconus. *Cornea*. 2012;31:627-632.
25. Bermansson JP, Goosey JD, Chirag KP, et al. Recurrence or re-emergence of keratoconus - what is the evidence telling us? Literature review and two case reports. *Ocul Surf*. 2014;12:267-272.
26. Busin M, Madi S, Scorcia V, et al. A two-piece microkeratome-assisted mushroom keratoplasty improves the outcomes and survival of grafts performed in eyes with diseased stroma and healthy endothelium (an American Ophthalmological Society Thesis). *Trans Am Ophthalmol Soc*. 2015;113:T11-T122.
27. Saelens IE, Bartels MC, Van Rij G. Manual trephination of mushroom keratoplasty in advanced keratoconus. *Cornea*. 2008;27:650-655.
28. Farid M, Steinert RF. Femtosecond laser-assisted corneal surgery. *Curr Opin Ophthalmol*. 2010;21:288-292.
29. Mian SI, Shtein RM. Femtosecond laser-assisted corneal surgery. *Curr Opin Ophthalmol*. 2007;18:295-299.
30. Bahar I, Kaiserman I, McAllum P, Rootman D. Femtosecond laser-assisted penetrating keratoplasty: stability evaluation of different wound configurations. *Cornea*. 2008;27:209-211.
31. Sugar A, Rapuano CJ, Culbertson WW, et al. Laser in situ keratomileusis for myopia and astigmatism: safety and efficacy: a report by the American Academy of Ophthalmology. *Ophthalmology*. 2002;109:175-187.
32. Shehadeh-Mashor R, Chan CC, Bahar I, et al. Comparison between femtosecond laser mushroom configuration and manual trephine straight-edge configuration deep anterior lamellar keratoplasty. *Br J Ophthalmol*. 2014;98:35-39.
33. McAllum PJ, Segev F, Herzig S, et al. Deep anterior lamellar keratoplasty for post-LASIK ectasia. *Cornea*. 2007;26:507-511.
34. Smadja D, Colin J, Krueger RR, et al. Outcomes of deep anterior lamellar keratoplasty for keratoconus: learning curve and advantages of the big bubble technique. *Cornea*. 2012;31:859-863.
35. Ghanem RC, Bogoni A, Ghanem VC. Pachymetry-guided intrastromal air injection ("pachy-bubble") for deep anterior lamellar keratoplasty: results of the first 110 cases. *Cornea*. 2015;34:625-631.

Footnotes and Financial Disclosures

Originally received: December 30, 2016.
Final revision: January 30, 2017.
Accepted: February 9, 2017.
Available online: March 20, 2017. Manuscript no. 2016-1190.

[1] Ospedale Privato "Villa Igea," Department of Ophthalmology, Forlì, Italy.

[2] Istituto Internazionale per la Ricerca e Formazione in Oftalmologia, Forlì, Italy.

[3] Ospedale "SS. Giovanni e Paolo," Department of Ophthalmology, Venezia, Italy.

[4] Rabin Medical Center, Department of Ophthalmology, Petah Tikva, Israel.

[5] Sackler Faculty of Medicine, Tel Aviv University, Tel Aviv, Israel.

[6] University of "Magna Graecia," Department of Ophthalmology, Catanzaro, Italy.

Presented in part as a poster at the Annual Meetings of the American Academy of Ophthalmology in Las Vegas, November 14−17, 2015, and Chicago, October 15−18, 2016.

Financial Disclosure(s):
The author(s) have no proprietary or commercial interest in any materials discussed in this article.

M.B.: Reimbursement of travel expenses and royalties −Moria, Antony, France.

Author Contributions:

Conception and design: Busin

Data collection: Busin, Leon, Nahum, Scorcia

Analysis and interpretation: Leon, Nahum

Obtained funding: Not applicable

Overall responsibility: Busin, Leon, Nahum, Scorcia

Abbreviations and Acronyms:
AS-OCT = anterior segment optical coherence tomography; **BSCVA** = best spectacle-corrected visual acuity; **CCT** = central corneal thickness; **D** = diopters; **DALK** = deep anterior lamellar keratoplasty; **KC** = keratoconus; **logMAR** = logarithm of the minimum angle of resolution; **PK** = penetrating keratoplasty.

Correspondence:
Massimo Busin, MD, Ospedale Privato "Villa Igea," Department of Ophthalmology, 47122 Forlì, Italy. E-mail: mbusin@yahoo.com.