

# A Modified Technique for Descemet Membrane Stripping Automated Endothelial Keratoplasty to Minimize Endothelial Cell Loss

Massimo Busin, MD; Priya R. Bhatt, MRCOphth; Vincenzo Scorcia, MD

**I**n an attempt to enhance postoperative survival of donor endothelium, the conventional technique for Descemet membrane stripping automated endothelial keratoplasty (DSAEK) was modified using the prototype of a glide specially designed to facilitate graft delivery and minimize surgical trauma. Instead of using the so-called taco technique, the Busin glide is loaded with the donor lamella, and a microincision forceps is inserted into a temporal side entry and passed across the anterior chamber, exiting through a nasal clear cornea tunnel to grab the graft and drag it into the eye. In 10 patients who underwent DSAEK, mean (SD) postoperative endothelial cell loss was 20.0% (2.6%) at 6 months, 23.5% (2.8%) at 12 months, and 26.4% (2.7%) at 18 to 24 months. Reduced trauma to the graft using our modified technique limits endothelial cell loss after DSAEK to the level recorded after conventional penetrating keratoplasty (PK).

*Arch Ophthalmol.* 2008;126(8):1133-1137

Descemet membrane stripping automated endothelial keratoplasty (DSAEK) involves mechanical stripping of diseased host endothelium and Descemet membrane and replacement with a donor graft of endothelium, Descemet membrane, and a thin layer of posterior stroma harvested with an automated microkeratome.<sup>1</sup> Compared with penetrating keratoplasty (PK), visual rehabilitation after DSAEK is faster and postoperative refractive error is lower, more predictable, and stable.<sup>2-4</sup>

However, with the current technique, major trauma to the donor endothelium is caused by tissue manipulation in folding the graft like a taco and positioning it.<sup>2,3</sup> As a result, postoperative endothelial cell survival is substantially lower with DSAEK than with conventional PK.<sup>2,3</sup> We report the clinical results and the postoperative endothelial cell loss, determined between 6 and 24 months after surgery, in the first 10 consecutive patients who underwent a modified DSAEK in which a pull-through technique was used for graft delivery with the help of a glide specially developed to reduce manipulation of donor tissue.

**Author Affiliations:** Departments of Ophthalmology, Villa Serena Hospital, Forlì, and University Magna Graecia, Catanzaro, Italy (Drs Busin and Scorcia); and Ophthalmology Department, Royal Bolton Hospital, Bolton, England (Dr Bhatt).

## METHODS

In 2005, a modified DSAEK was performed by one of us (M.B.) in 10 consecutive patients with pseudophakia and endothelial decompensation who were enrolled in a prospective evaluation. Details of patient history and preoperative examination are given in **Table 1**.

*For editorial comment  
see page 1140*

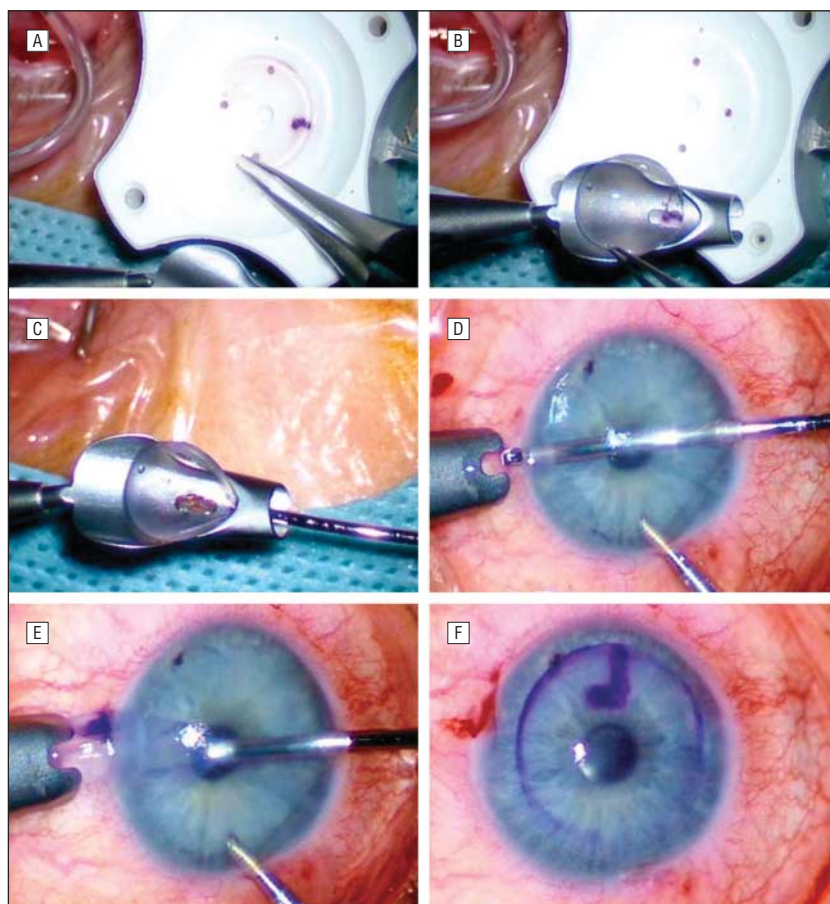
Four to 6 weeks postoperatively, sutures were removed in all patients. At 6, 12, and 18 to 24 months after DSAEK, each patient underwent a complete evaluation including both uncorrected and best spectacle-corrected visual acuity, refraction, keratometry, corneal topography analysis (EyeSys 2000; EyeSys Technologies, Inc, Houston, Texas), and endothelial cell count obtained using a contact endothelial camera (cornea module of HRT II; Heidelberg Engineering GmbH, Heidelberg, Germany) from the central cornea. The side camera of the contact endothelial system and an external fixation mire were used to align the eye properly. Postoperative endothelial counts were compared with those obtained preoperatively by the eye bank for the donor corneas using light microscopy after vital staining with trypan blue, and cell loss was determined as a percentage of the preoperative in vitro value.

**Table 1. Preoperative Data for Patients Undergoing Modified DSAEK**

Patient No.	Patient Data		Preoperative VA <sup>a</sup>	Follow-up, mo
	Sex/Age, y	Preoperative Diagnosis		
1	M/71	Fuchs dystrophy	20/200	24
2	M/80	PBK	HM	24
3	F/90	PBK	20/400	24
4	F/65	Fuchs dystrophy	20/100	24
5	M/77	PBK	20/100	22
6	F/74	PBK	CF	22
7	F/62	Fuchs dystrophy	20/80	22
8	M/64	Fuchs dystrophy	20/100	22
9	F/69	Fuchs dystrophy	20/200	18
10	F/84	Fuchs dystrophy	20/200	18

Abbreviations: CF, counting fingers; DSAEK, Descemet membrane stripping automated endothelial keratoplasty; F, female; HM, hand motion; M, male; PBK, pseudophakic bullous keratopathy; VA, visual acuity.

<sup>a</sup>Not improvable owing to corneal edema.



**Figure 1.** Pull-through technique for graft delivery in Descemet membrane stripping automated endothelial keratoplasty. A corneal forceps is used to grasp the edge of the graft (A) and place the tissue on the plate of the specially designed Busin glide (Moria SA, Antony, France), keeping the endothelial side up (B). Then the graft is pulled into the funnel-shaped part of the Busin glide using a microincision forceps until it engages the Busin glide opening (C). The same microincision forceps is inserted through the side entry and passed across the anterior chamber, exiting through the clear cornea tunnel to grab the graft from the Busin glide (D) and drag it into the anterior chamber (E). The donor lamella is allowed to unfold spontaneously under continuous irrigation from the anterior chamber maintainer (F).

Although 2 different methods were used for the comparison, cells were counted manually in an area of definite extension and magnification (fixed-frames

analysis) in both cases, and precise calibration of both systems, performed either by internal validation (light microscopy) or by the instrument manufac-

turer (specular microscopy) enabled us to use them variously without significant difference, as also demonstrated by Thuret et al.<sup>5</sup>

### SURGICAL TECHNIQUE

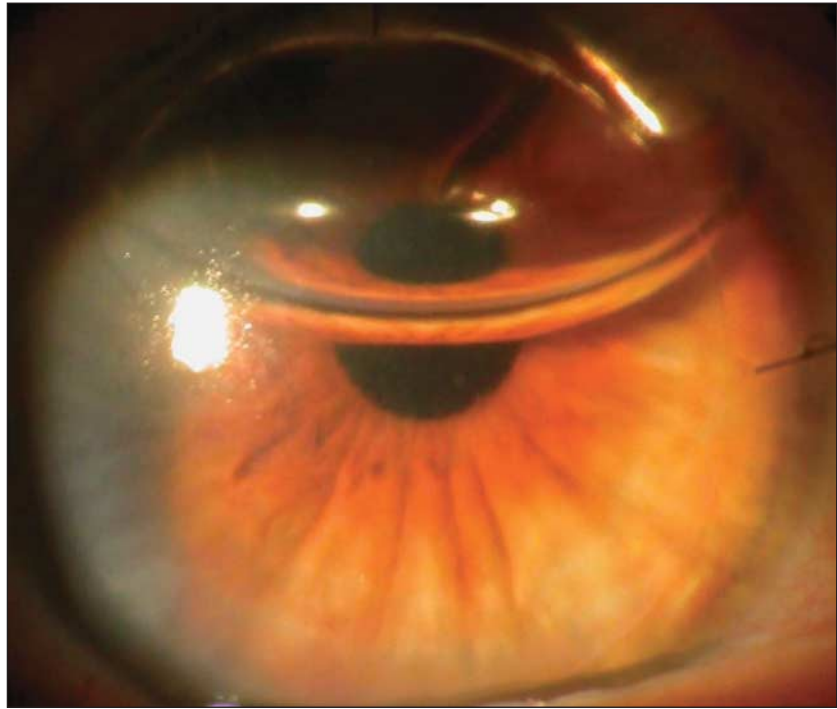
A detailed informed consent form was signed by all 10 patients undergoing surgery. Patients were sedated with intravenous droperidol, 3 mL (7.5 mg), immediately before peribulbar injection of local anesthetic, which consisted of a mixture of lidocaine hydrochloride, 2%, and bupivacaine hydrochloride, 0.5%.

The entire procedure was performed with the surgeon sitting at the 12-o'clock position. A marker 9 mm in diameter was used at the beginning of the procedure to outline the limits of the internal surface from which the endothelium was to be peeled off. Then the anterior chamber was entered at the 12-o'clock position with a 25-gauge needle mounted on a 2.5-mL empty syringe. Aqueous (approximately 0.2-0.4 mL) was aspirated and air was injected, filling the anterior chamber. The tip of the needle was bent upward before introduction and was used to cut through the endothelium and Descemet membrane, following the contour of the superficial mark. The needle was retracted, and a 25-gauge blunt cannula was mounted on the syringe and reinserted through the same puncture site. The cannula was used to sweep away the endothelium and Descemet membrane, usually in a single

piece. Whenever air was lost, the anterior chamber was re-formed by injecting additional air with the syringe. Performing the entire maneuver under air enabled perfect visualization of the Descemet membrane (no dye was ever used) and eliminated the need for any viscoelastic substance in the anterior chamber. A clear cornea tunnel, 1 mm long and 3.2 mm wide, was prepared nasally. At this point, a peripheral iridectomy was performed, if not already present.

The donor lenticles were prepared using the automated lamellar therapeutic keratoplasty system (ALTK; Moria SA, Antony, France). After coating the endothelial side with a viscoelastic substance, the donor cornea was mounted on the artificial anterior chamber of the automated lamellar therapeutic keratoplasty system and most of the anterior stroma was removed using a microkeratome with a 300- $\mu$ m head. The stromal side of the resulting tissue was marked to facilitate correct intraoperative orientation of the graft. The posterior donor lamella was placed on a Barron punch with the endothelial side up and cut to the desired diameter (8.5-9.0 mm).

An anterior chamber maintainer was placed at the 12-o'clock position to enable continuous irrigation while performing the next surgical steps. The donor tissue was not folded and inserted into the anterior chamber with the so-called taco technique. Rather, a corneal forceps was used to grasp the edge of the graft (**Figure 1A**) and drag it onto the plate of the specially designed Busin glide (Moria SA), keeping the endothelial side up (**Figure 1B**). Then the tissue was pulled into the funnel-shaped part of the Busin glide using a microincision forceps until it engaged the Busin glide opening (**Figure 1C**). A side entry was created temporarily. The Busin glide was then inverted and positioned at the entrance of the nasal clear cornea tunnel. The same microincision forceps (held in the left hand when operating on the left eye and in the right hand when operating on the right eye) was inserted through the side entry and passed across the anterior cham-



**Figure 2.** Operated eye of patient 8 in the series on postoperative day 1. The cornea has already cleared completely, although air is still present in the anterior chamber. At the 6-month follow-up uncorrected visual acuity was 20/20.

ber, exiting through the clear cornea tunnel to grab the graft from the Busin glide (**Figure 1D**) and drag it into the anterior chamber (**Figure 1E**). No additional viscoelastic substance was required during insertion because adequate coating of the donor endothelium was provided by residua from the graft preparation. The donor lamella was allowed to unfold spontaneously under continuous irrigation from the anterior chamber maintainer (**Figure 1F**). When necessary, centering of the graft was achieved by gentle tapping on the corneal surface. Both the clear cornea tunnel and the side entry were sutured watertight with interrupted 10-0 nylon sutures. The graft was attached to the posterior corneal surface by filling the anterior chamber with air injected through the temporal side entry. Triamcinolone acetonide and gentamicin sulfate, 0.3%, were injected subconjunctivally at the end of the procedure. After surgery, a pressure patch was kept in place overnight, and patients were instructed to lie on their backs for 6 to 8 hours. Beginning the next morning, dexamethasone phosphate, 0.1%, and tobramycin sulfate, 0.3%, antibiotic eyedrops were adminis-

tered every 2 hours, then tapered over 3 to 4 months to a single daily steroidal administration, which was continued indefinitely. In each patient, all sutures were removed 4 to 6 weeks after DSAEK (Video available at <http://www.archophthalmol.com>).

## RESULTS

Surgery was uneventful in all patients and was completed within 45 minutes. All corneas were clear on the first postoperative day, when air still filled about half of the anterior chamber (**Figure 2**). No postoperative complications were recorded. Data collected at postoperative examinations are given in **Table 2**.

Six months after surgery, uncorrected visual acuity was at least 20/60 in the operated-on eye in 8 of 10 patients, and best spectacle-corrected visual acuity ranged between 20/10 and 20/20. In 4 patients, vision was limited by the presence of age-related macular degeneration at various stages of progression. No substantial changes in either uncorrected visual acuity or best spectacle-corrected visual acu-

**Table 2. Postoperative Data in Patients Undergoing Modified DSAEK**

Patient Data	Patient No.									
	1	2	3	4	5	6	7	8	9	10
<b>UCVA</b>										
Follow-up, mo										
6	20/60	20/100	20/60	20/40	20/30	20/200	20/50	20/20	20/30	20/50
12	20/50	20/100	20/50	20/30	20/30	20/100	20/50	20/20	20/25	20/50
18-24	20/50	20/100	20/50	20/30	20/30	20/100	20/50	20/20	20/25	20/50
<b>BCVA</b>										
Follow-up, mo										
6	20/20	20/60	20/40	20/25	20/25	20/100	20/30	20/20	20/40	20/25
12	20/20	20/60	20/40	20/25	20/25	20/100	20/40	20/20	20/20	20/25
18-24	20/20	20/60	20/30	20/25	20/25	20/100	20/40	20/20	20/20	20/25
<b>Spherical Equivalent, D</b>										
Follow-up, mo										
6	+1.00	+1.25	+0.50	-0.50	+0.25	+1.00	-0.50	0.00	+0.50	+0.50
12	+0.75	+1.25	-0.50	-0.50	+0.25	+0.75	-0.50	0.00	+0.25	-0.50
18-24	+0.75	+1.25	-0.50	-0.50	+0.25	+0.75	-0.50	0.00	+0.25	-0.50
<b>Refractive Astigmatism, D</b>										
Follow-up, mo										
6	0.25	1.50	1.00	0.50	0.75	1.25	1.00	0.25	1.00	0.25
12	0.50	1.50	1.00	0.75	0.75	1.00	1.00	0.25	0.75	0.75
18-24	0.50	1.25	1.00	0.75	0.75	1.00	1.00	0.25	1.00	0.75
<b>Keratometric Reading, Mean, D</b>										
Follow-up, mo										
6	43.50	43.00	42.50	43.50	41.25	41.75	42.75	42.50	42.00	41.25
12	43.00	43.00	42.50	43.25	41.25	41.75	42.75	42.50	42.50	41.25
18-24	43.00	43.50	42.50	43.25	41.25	41.50	42.75	42.50	42.00	41.25
<b>ECL</b>										
Follow-up, mo										
6	22.1	24.9	18.4	16.7	17.0	19.9	19.6	20.1	18.4	16.5
12	22.5	28.2	24.2	20.2	25.1	22.6	26.0	18.9	25.2	21.8
18-24	22.9	31.1	27.6	27.4	25.8	24.2	25.9	28.2	28.2	22.5
<b>Total Duration of Follow-up, mo</b>	<b>24</b>	<b>24</b>	<b>24</b>	<b>24</b>	<b>22</b>	<b>22</b>	<b>22</b>	<b>22</b>	<b>18</b>	<b>18</b>

Abbreviations: BCVA, best spectacle-corrected visual acuity; D, diopter; DSAEK, Descemet membrane stripping automated endothelial keratoplasty; ECL, endothelial cell loss in percentage from preoperative eye bank value; UCVA, uncorrected visual acuity.

ity were recorded at the following examinations.

Six months after DSAEK, the refractive spherical equivalent ranged from +1.25 to -0.50 diopters (D). Mean keratometric readings varied between 41.25 and 43.50 D. Refractive astigmatic error was equal to or less than 1.50 D in all patients. Refractive and keratometric values recorded at later examinations did not differ substantially from those obtained 6 months after DSAEK. Regular astigmatism of low degree was demonstrated at computerized analysis of corneal topography in all patients at all examinations. Endothelial cell loss ranged from 16.5% to 24.9% at 6 months (mean [SD], 20.0% [2.6%]), from 18.9% to 28.2% at 12 months (23.5% [2.8%]), and from 22.5% to 31.1% (26.4% [2.7%])

at the last examination at 18 to 24 months after DSAEK.

### COMMENT

In an attempt to optimize visual and refractive results, while simplifying the technique and minimizing complications, posterior lamellar keratoplasty has undergone continuous refinement, from the introduction of deep lamellar endothelial keratoplasty (DLEK)<sup>6-9</sup> to the development of Descemet membrane stripping and endothelial keratoplasty (DSEK)<sup>9-14</sup> to DSAEK,<sup>1-3,5</sup> and, more recently, to Descemet membrane and endothelial keratoplasty (DMEK).<sup>10</sup> In particular, DSAEK has gained favor with most surgeons because microkeratome-assisted dissec-

tion of the donor cornea eliminates the complications associated with manual dissection<sup>1-3</sup> while making surgery faster and simpler.

A major disadvantage of DSAEK is that the endothelial cell loss determined 1 to 2 years postoperatively is substantially higher<sup>2-3</sup> than that recorded after conventional PK.<sup>14-16</sup> Folding of the donor button in a taco configuration, squeezing of the graft between forceps for insertion, crushing of the tissue while passing through the surgical wound, and further manipulation often necessary to unfold the graft inside the anterior chamber are the primary causes of endothelial damage, resulting in reduced postoperative endothelial cell density.

The modified technique described herein simplifies surgery and



considerably shortens the time necessary for performing DSAEK by eliminating most of the maneuvers necessary to fold and unfold the donor graft during delivery. The graft passing through the opening of the Busin glide is shaped like a flat cylinder, with the inner endothelial lining protected against traumatic contact by a thin layer of viscoelastic substance. The tissue roll can be easily pulled into the anterior chamber while its sides freely slide on each other to conform to the characteristics of the clear cornea tunnel. The tissue is not crushed as in the taco technique, and trauma is minimized. In addition, while the graft engages the surgical wound (Figure 1E), the anterior chamber is sealed and the surgeon can operate under closed-system conditions. Once the delivery is completed, the clear cornea tunnel closes and the graft unfolds spontaneously, in most cases, as a consequence of continuous irrigation from the anterior chamber maintainer. With the taco technique, insertion of the graft through the surgical wound with a forceps is often difficult because the flow from the anterior chamber maintainer tends to expel the graft and the anterior chamber collapses.

Another relevant result of our substantial simplification of the DSAEK is the marked reduction in surgical time. All procedures in this series were completed within 45 minutes. This is even more stunning when considering that the surgeon (M.B.) had previously performed only 10 other DSAEKs, all requiring at least 60 minutes of surgical time.

An additional and probably most important advantage of our approach is that the donor endothelium remains protected during the entire procedure. Possibly damaging maneuvers such as folding the graft, squeezing the tissue through the surgical wound with a forceps, or touching the endothelial surface

with various instruments while trying to unfold the graft are eliminated. In addition, the persistence of a viscoelastic coating on the internal surface of the graft protects the endothelium if the edges curl over each other while the tissue roll flattens and is dragged through the incision. As a result, endothelial cell loss averaged 26.4% between 18 and 24 months postoperatively, a value far below those reported at earlier postoperative times after DSAEK or DSEK (up to 50%)<sup>2,3</sup> and similar, if not lower, than those recorded after conventional PK (up to 30%).<sup>14-16</sup>

In conclusion, our preliminary data indicate that transition from the taco technique to the pull-through technique with Busin glide minimizes postoperative endothelial cell loss with DSAEK to a level comparable to that recorded after conventional PK, eliminating the primary argument against the use of DSAEK for the treatment of endothelial failure.

**Submitted for Publication:** September 7, 2007; final revision received December 4, 2007; accepted December 16, 2007.

**Correspondence:** Massimo Busin, MD, Department of Ophthalmology, Villa Serena Hospital, Via Sisa 33, 47100 Forlì, Italy (mbusin@yahoo.com).

**Financial Disclosure:** Dr Busin was reimbursed in part by Moria SA, for travel expenses incurred during 2005-2007. Beginning in January 2008, Dr Busin is receiving royalties from the Busin glide (Moria SA).

**Additional Information:** The Video is available at <http://www.archophthalmol.com>.

## REFERENCES

- Gorovoy MS. Descemet-stripping automated endothelial keratoplasty. *Cornea*. 2006;25(8):886-889.
- Koenig SB, Covert DJ. Early results of small-incision Descemet's stripping and automated endothelial keratoplasty. *Ophthalmology*. 2007; 114(2):221-226.
- Koenig SB, Covert DJ, Dupps WJ Jr, Meisler DM. Visual acuity, refractive error, and endothelial cell density six months after Descemet stripping and automated endothelial keratoplasty (DSAEK). *Cornea*. 2007;26(6):670-674.
- Price MO, Price FW Jr. Descemet's stripping with endothelial keratoplasty: comparative outcomes with microkeratome-dissected and manually dissected donor tissue. *Ophthalmology*. 2006;113(11):1936-1942.
- Thuret G, Deb-Joardar N, Manissolle C, et al. Assessment of the human corneal endothelium: in vivo Topcon SP2000P specular microscope versus ex vivo sambacornea eye bank analyser. *Br J Ophthalmol*. 2007;91(2):265-266.
- Melles GR, Eggink FA, Lander F, et al. A surgical technique for posterior lamellar keratoplasty. *Cornea*. 1998;17(6):618-626.
- Terry MA, Ousley PJ. Rapid visual rehabilitation after endothelial transplants with deep lamellar endothelial keratoplasty (DLEK). *Cornea*. 2004; 23(2):143-153.
- Ousley PJ, Terry MA. Stability of vision, topography, and endothelial cell density from 1 year to 2 years after deep lamellar endothelial keratoplasty surgery. *Ophthalmology*. 2005;112(1): 50-57.
- Terry MA, Ousley PJ. Deep lamellar endothelial keratoplasty visual acuity, astigmatism, and endothelial survival in a large prospective series. *Ophthalmology*. 2005;112(9):1541-1548.
- Melles GR. Posterior lamellar keratoplasty: DLEK to DSEK to DMEK. *Cornea*. 2006;25(8):879-881.
- Price FW Jr, Price MO. Descemet's stripping with endothelial keratoplasty in 200 eyes: early challenges and techniques to enhance donor adherence. *J Cataract Refract Surg*. 2006;32(3):411-418.
- Price MO, Price FW. Descemet's stripping endothelial keratoplasty. *Curr Opin Ophthalmol*. 2007; 18(4):290-294.
- Mearza AA, Qureshi MA, Rostron CK. Experience and 12-month results of Descemet-stripping endothelial keratoplasty (DSEK) with a small-incision technique. *Cornea*. 2007;26(3):279-283.
- Price FW Jr, Price MO. Descemet's stripping with endothelial keratoplasty in 50 eyes: a refractive neutral corneal transplant. *J Refract Surg*. 2005; 21(4):339-345.
- Langenbacher A, Seitz B, Nguyen NX, Naumann O. Corneal endothelial cell loss after nonmechanical penetrating keratoplasty depends on diagnosis: a regression analysis. *Graefes Arch Clin Exp Ophthalmol*. 2002;240(5):387-392. doi:10.1007/s00417-002-0470-2.
- Bourne WM, Nelson LR, Maguire LJ, Baratz KH, Hodge DO. Comparison of Chen medium and Optisol-GS for human corneal preservation at 4 degrees C: results of transplantation. *Cornea*. 2001; 20(7):683-686.
- Ing JJ, Ing HH, Nelson LR, Hodge DO, Bourne WM. Ten-year postoperative results of penetrating keratoplasty. *Ophthalmology*. 1998;105(10):1855-1865.