

Combined Descemet-stripping automated endothelial keratoplasty and phacoemulsification with toric intraocular lens implantation for treatment of failed penetrating keratoplasty with high regular astigmatism

Vincenzo Scorgia, MD, Andrea Lucisano, MD, Jacqueline Beltz, FRANZCO, Massimo Busin, MD

We present the case of a 57-year-old woman who had combined Descemet-stripping automated endothelial keratoplasty (DSAEK) and phacoemulsification with implantation of a toric intraocular lens (IOL). Surgery was intended to treat a cataract developing in a post-penetrating keratoplasty (PKP) eye with high astigmatism and endothelial decompensation. Six months after uneventful surgery, the cornea was clear and the corrected distance visual acuity was 20/20 with a refraction of $+0.25 -1.00 \times 10$ (from $-3.00 -8.50 \times 12$ preoperatively). The internal topography map (OPD-Scan) showed an IOL rotation of 4 degrees. The endothelial cell loss was 15% of the eye-bank value. Descemet-stripping automated endothelial keratoplasty combined with phacoemulsification and toric IOL implantation is a relatively simple and very effective procedure for eyes with endothelial failure and high post-PKP astigmatism. The speed of visual rehabilitation and final visual acuity achieved with this approach was superior to that obtained with other surgical procedures.

Financial Disclosure: Dr. Busin received royalties from Moria in 2008, 2009, and 2010, and his travel expenses were partly reimbursed by Moria from 2005 to 2011. No other author has a financial or proprietary interest in any material or method mentioned.

J Cataract Refract Surg 2012; 38:716–719 © 2012 ASCRS and ESCRS

Currently, Descemet-stripping automated endothelial keratoplasty (DSAEK) is the surgical procedure of choice for the treatment of endothelial failure after penetrating keratoplasty (PKP).^{1–5} However, if high astigmatism is present as a result of the PKP, it remains substantially unaffected by DSAEK and visual acuity is unlikely to improve postoperatively despite the recovery of corneal clarity.^{5,6} Recently, moderate or high astigmatism resulting from PKP has been successfully

corrected by implantation of a toric intraocular lens (IOL) alone (phakic IOL) or in combination with phacoemulsification.^{7–11} We report the outcome of a combined procedure of DSAEK and phacoemulsification with implantation of a hydrophilic acrylic bitoric IOL to treat high regular corneal astigmatism in a patient with cataract in a failed PKP.

CASE REPORT

A 57-year-old woman presented to our institution complaining of a progressive decrease in visual acuity in her left eye. Penetrating keratoplasty for keratoconus had been performed in that eye in 1995. Since then, the acuity had been affected by anisometropia and high regular astigmatism, which could be only partly corrected by spectacles. The patient was intolerant to hard contact lenses.

On presentation, the uncorrected distance visual acuity (UDVA) and corrected distance visual acuity (CDVA) were 20/400 and 20/200, respectively, with a manifest refraction of $-3.00 -8.50 \times 12$. Slitlamp examination showed a full-thickness graft (8.5 mm in diameter) with mild edema and a dense nuclear cataract (Figure 1, A). Endothelial cell

Submitted: August 5, 2011.

Final revision submitted: September 22, 2011.

Accepted: September 22, 2011.

From the Department of Ophthalmology (Scorgia, Lucisano, Busin), Magna Graecia University, Catanzaro and the Department of Ophthalmology (Beltz, Busin), Villa Igea Hospital, Forlì, Italy.

Corresponding author: Vincenzo Scorgia, MD, Via dei Crociati 40, 88100 Catanzaro, Italy. E-mail: vscorgia@libero.it.

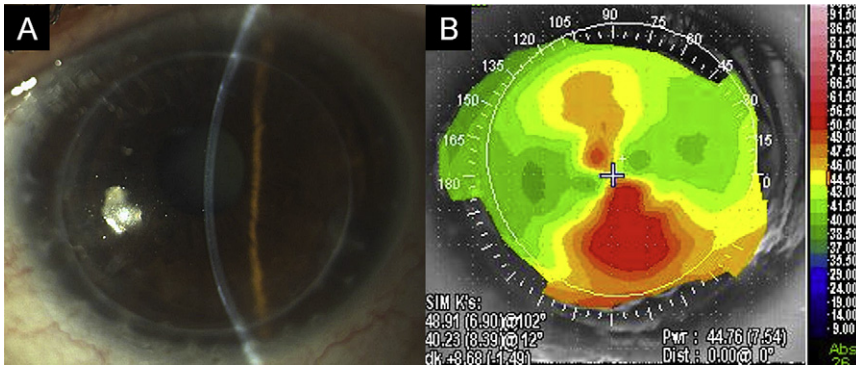


Figure 1. A: Preoperative digital slitlamp image of the anterior segment showing corneal graft edema and dense nuclear lens opacity. B: Topographic anterior axial curvature map showing the high degree of astigmatism resulting from the previous PKP.

density could not be evaluated as the noncontact specular microscope (Topcon SP2000P, Topcon Corp.) could not obtain a useful picture of the endothelial surface. Corneal topography (OPD-Scan, Nidek Co. Ltd.) showed high astigmatism with a regular asymmetrical bowtie pattern (Figure 1, B); keratometry values (K1/K2) were 48.91/40.23 @ 102°.

Before surgery, the patient was asked to sit at the slitlamp. After the beam was set horizontally, a sterile ink pencil was used to mark the 0- and 180-degree positions, thus compensating for cyclorotation. Local anesthesia was administered with a peribulbar injection of a mixture of lidocaine hydrochloride 2.0% and bupivacaine hydrochloride 0.5%. Standard phacoemulsification was performed through a 2.2 mm clear corneal tunnel centered on the steepest corneal axis previously marked using a Mendez ring.

The customized hydrophilic acrylic bitoric IOL (AT TOR-BI 709M-Acri.Confort 646TCL, Carl Zeiss Meditec AG) was manufactured based on the biometric data obtained by partial coherence interferometry (PCI) (IOLMaster, Carl Zeiss Meditec AG). The IOL power was +12.5 + 8.0, which included an intended overcorrection of 0.75 D to compensate for the mild hyperopic shift usually seen after DSAEK surgery. The IOL was implanted in the capsular bag and then rotated until proper alignment with the planned axis was achieved. The pupil was constricted with acetylcholine chloride (Miochol-E), and the clear corneal tunnel was widened to 4.0 mm. The anterior chamber was filled with air, and the Descemet membrane and endothelium were peeled off in a single piece. At this point, a small peripheral iridectomy was performed at the 6 o'clock position with a vitrectome to prevent the possible onset of pupillary block.

The donor lenticule, prepared using the automated lamellar therapeutic keratoplasty system (Moria), was then

placed on a Barron punch (Katena Products, Inc.), endothelial side up, and trephined to 9.0 mm in diameter. An anterior chamber maintainer was placed at the 12 o'clock position for continuous irrigation, and the donor tissue was inserted into the anterior chamber with the pull-through technique using the Busin glide (Moria). Both the clear corneal tunnel and the side entries were sutured tightly with interrupted 10-0 nylon sutures, and the anterior chamber was filled with air injected through the temporal side entry. Triamcinolone acetonide and gentamicin were injected subconjunctivally at the end of the procedure. The patient was pressure-patched overnight and instructed to lie supine for 6 to 8 hours. Postoperatively, dexamethasone phosphate 0.1% and tobramycin antibiotic eyedrops were administered initially every 2 hours and then tapered over 3 to 4 months. All sutures were removed 3 weeks after surgery. No intraoperative or postoperative complications occurred.

By 1 month postoperatively, the UDVA was 20/30 and the CDVA was 20/25 with a refraction of +0.75 -1.50 × 10. At the last follow-up, 6 months postoperatively, the corneal graft was transparent and the central endothelial cell density, measured with a noncontact specular microscope, was 2210 cells/mm², representing a 15% cell loss from the initial eye-bank count (2600 cells/mm²). The CDVA had improved to 20/20 with a minimal change in refraction (+0.25 -1.00 × 10) compared with the 1-month measurement. The keratometry readings had not changed substantially from the preoperative values. The alignment of the toric IOL was evaluated by slitlamp examination and further confirmed by the wavefront analysis and internal refractive map obtained with the topography system that showed a postoperative IOL rotation of 4 degrees from the intended axis (Figure 2).

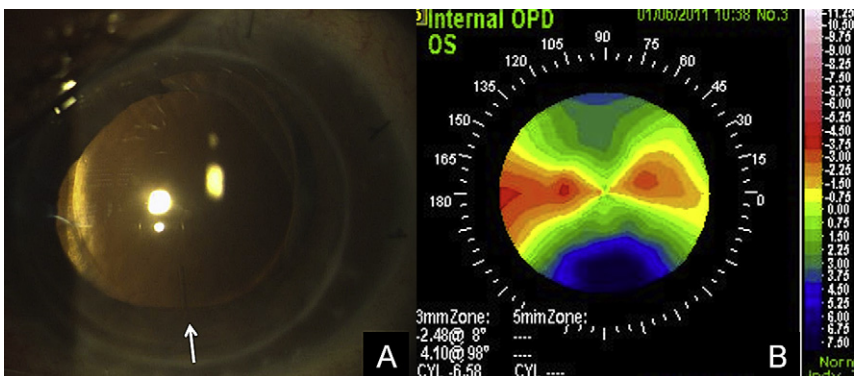


Figure 2. A: One week postoperatively, the digital slitlamp image of the anterior segment shows a transparent corneal graft. The IOL is aligned with the steepest corneal meridian (white arrow). B: Six months after surgery, the internal refractive map obtained with the topography system shows the power and axis of the implanted toric IOL.

DISCUSSION

Several authors have recently reported that a triple procedure combining DSAEK, phacoemulsification, and IOL implantation allows rapid visual rehabilitation with minimal surgically induced astigmatism and/or ametropia.^{5,12} However, performing this triple procedure in an eye with a full-thickness edematous graft has the potential limitation of not correcting the high astigmatism that may be present in up to 20% of cases.¹³ In these cases, after the cornea has cleared following DSAEK, additional surgery is required to allow spectacle correction. Incisional surgery and/or excimer laser procedures (both photorefractive keratectomy and laser in situ keratomileusis) have been used in the past but have had variable refractive results, ie, undercorrection, overcorrection, and/or regression of effect over time, as well as relatively high rates of other complications, including perforation, wound gaping, infection, and loss of CDVA.^{14–19}

Another option would be to combine cataract surgery with a repeat PKP, but this approach would expose the patient to a renewed higher immunologic risk as well as other PKP-related possible complications. In addition, at least 1 year would be required before all sutures could be removed and final refraction achieved.

Recently, phacoemulsification and implantation of a customized toric IOL have been suggested as a safe and effective procedure for the correction of high astigmatism resulting from PKP, pellucid marginal degeneration, and keratoconus.^{10,20,21} Our case demonstrates that toric IOLs have an additional indication in eyes with full-thickness corneal grafts that are visually impaired due to the development of cataract as well as the presence of endothelial failure and high post-PKP astigmatism. In these eyes, a toric IOL can be implanted at the time of combined DSAEK and phacoemulsification, thus effectively treating all conditions negatively affecting vision with a single procedure. As with the procedures reported in the past,^{11,22} the toric IOL in our case exhibited minimal rotation from the intended position and good stability despite the additional maneuvers required during DSAEK, particularly the complete air fill of the anterior chamber and its consequent pronounced deepening.

A potential limitation of our approach concerns the calculation of the toric IOL. The accuracy of this calculation may have been negatively affected by 2 factors. First, the corneal edema may have prevented the PCI from measuring as precisely as in the presence of a clear cornea. Second, the 4.0 mm wide clear corneal tunnel that we routinely use for DSAEK may have caused an unpredictable change in corneal

curvature in this post-PKP eye compared with the effect in an unoperated eye. Therefore, we decided not to consider the theoretical calculations of surgically induced astigmatism during the IOL calculation, as to date these have not been validated in the setting of PKP. However, in cases such as this, the aim of surgery is to obtain a debulking effect, that is, to achieve a postoperative refractive error that can be corrected with spectacles, and the above-mentioned variables have had a negligible effect in this respect. Minor residual ametropia, including astigmatism, could then be addressed, if required, with more accurate procedures involving an excimer laser treatment.

In conclusion, this case describing implantation of a toric IOL at the time of combined cataract surgery and DSAEK in a post-PKP eye with high astigmatism shows that a 1-stage approach is at least as effective as other 2-stage or even 3-stage approaches. This procedure reduced postoperative recovery to a period of several weeks and allowed excellent final CDVA.

REFERENCES

1. Price MO, Price FW Jr. Descemet's stripping with endothelial keratoplasty; comparative outcomes with microkeratome-dissected and manually dissected donor tissue. *Ophthalmology* 2006; 113:1936–1942
2. Terry MA, Shamie N, Chen ES, Hoar KL, Friend DJ. Endothelial keratoplasty; a simplified technique to minimize graft dislocation, iatrogenic graft failure, and pupillary block. *Ophthalmology* 2008; 115:1179–1186
3. Busin M, Bhatt PR, Scorcia V. A modified technique for Descemet membrane stripping automated endothelial keratoplasty to minimize endothelial cell loss. *Arch Ophthalmol* 2008; 126:1133–1137. Available at: <http://archophth.ama-assn.org/cgi/reprint/126/8/1133.pdf>. Accessed September 28, 2011
4. Price FW Jr, Price MO. Endothelial keratoplasty to restore clarity to a failed penetrating graft. *Cornea* 2006; 25:895–899
5. Covert DJ, Koenig SB. Descemet stripping and automated endothelial keratoplasty (DSAEK) in eyes with failed penetrating keratoplasty. *Cornea* 2007; 26:692–696
6. Straiko MD, Terry MA, Shamie N. Descemet stripping automated endothelial keratoplasty under failed penetrating keratoplasty: a surgical strategy to minimize complications. *Am J Ophthalmol* 2011; 151:233–237
7. Sun X-Y, Vicary D, Montgomery P, Griffiths M. Toric intraocular lenses for correcting astigmatism in 130 eyes. *Ophthalmology* 2000; 107:1776–1781; discussion by RM Kershner, 1781–1782
8. Tehrani M, Stoffelns B, Dick HB. Implantation of a custom intraocular lens with a 30-diopter torus for the correction of high astigmatism after penetrating keratoplasty. *J Cataract Refract Surg* 2003; 29:2444–2447
9. Tahzib NG, Cheng YYY, Nuijts RMMA. Three-year follow-up analysis of Artisan toric lens implantation for correction of postkeratoplasty ametropia in phakic and pseudophakic eyes. *Ophthalmology* 2006; 113:976–984
10. de Sanctis U, Eandi C, Grignolo F. Phacoemulsification and customized toric intraocular lens implantation in eyes with cataract and high astigmatism after penetrating keratoplasty. *J Cataract Refract Surg* 2011; 37:781–785

11. Holland E, Lane S, Horn JD, Ernest P, Arleo R, Miller KM. The AcrySof toric intraocular lens in subjects with cataracts and corneal astigmatism; a randomized, subject-masked, parallel-group, 1-year study. *Ophthalmology* 2010; 117: 2104–2111
12. Terry MA, Shamie N, Chen ES, Phillips PM, Shah AK, Hoar KL, Friend DJ. Endothelial keratoplasty for Fuchs' dystrophy with cataract; complications and clinical results with the new triple procedure. *Ophthalmology* 2009; 116:631–639
13. Vail A, Gore SM, Bradley BA, Easty DL, Rogers CA, Armitage WJ, on behalf of collaborating surgeons. Conclusions of the corneal transplant follow-up study. *Br J Ophthalmol* 1997; 81:631–636. Available at: <http://www.ncbi.nlm.nih.gov/pmc/articles/PMC1722292/pdf/v081p00631.pdf>. Accessed September 28, 2011
14. Solomon A, Siganos CS, Frucht-Pery J. Relaxing incision guided by videokeratography for astigmatism after keratoplasty for keratoconus. *J Refract Surg* 1999; 15:343–348
15. Koay PYP, McGhee CNH, Crawford GJ. Effect of a standard paired arcuate incision and augmentation sutures on postkeratoplasty astigmatism. *J Cataract Refract Surg* 2000; 26: 553–561
16. Amm M, Duncker GIW, Schröder E. Excimer laser correction of high astigmatism after keratoplasty. *J Cataract Refract Surg* 1996; 22:313–317
17. Chang DH, Hardten DR. Refractive surgery after corneal transplantation. *Curr Opin Ophthalmol* 2005; 16:251–255
18. Busin M, Arffa RC, Zambianchi L, Lamberti G, Sebastiani A. Effect of hinged lamellar keratotomy on postkeratoplasty eyes. *Ophthalmology* 2001; 108:1845–1851; discussion by ED Donnenfeld, 1851–1852
19. Kwitko S, Marinho DR, Rymer S, Ramos Filho S. Laser in situ keratomileusis after penetrating keratoplasty. *J Cataract Refract Surg* 2001; 27:374–379
20. Visser N, Gast STJM, Bauer NJC, Nuijts RMMA. Cataract surgery with toric intraocular lens implantation in keratoconus: a case report. *Cornea* 2011; 30:720–723
21. Luck J. Customized ultra-high-power toric intraocular lens implantation for pellucid marginal degeneration and cataract. *J Cataract Refract Surg* 2010; 36:1235–1238
22. Chang DF. Comparative rotational stability of single-piece open-loop acrylic and plate-haptic silicone toric intraocular lenses. *J Cataract Refract Surg* 2008; 34:1842–1847



First author:

Vincenzo Scordia, MD

*Department of Ophthalmology,
Villa Igea Hospital, Forlì, Italy*